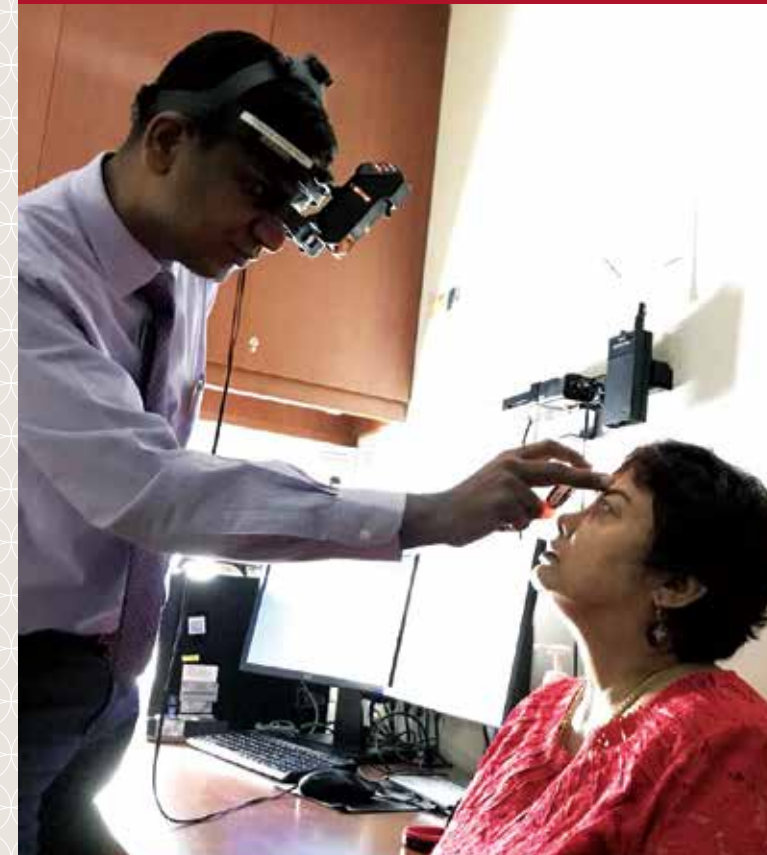

## What is the management of Posterior Uveitis?

- The treatment of uveitis differs with location and nature of the inflammatory process.
- As the inflammation is at the back of the eye and eye drops simply would not reach the affected area and hence needs a different approach.
- Thus the main mode of treatment in cases of posterior uveitis is systemic steroids (after ruling out infectious causes), which is generally taken in the form of tablet and occasionally in cases of sight-threatening conditions, steroid is administered through intravenous route.
- Also, it is necessary to treat the underlying disease. For example, if the posterior uveitis is caused by a virus then the antiviral drug will be administered by tablet or injection.

## DEPARTMENT OF OPHTHALMOLOGY

## Posterior Uveitis



### Clinic Appointments and Eye Screening

Subsidised: (65) 6357 7000  
Private: (65) 6357 8000  
Email: [eye@ttsh.com.sg](mailto:eye@ttsh.com.sg)  
Website: [www.ttsh.com.sg/eye](http://www.ttsh.com.sg/eye)

### LASIK Enquiries

Tel: (65) 6357 2255  
Email: [lasik@ttsh.com.sg](mailto:lasik@ttsh.com.sg)  
Website: [www.ttshlasik.com.sg](http://www.ttshlasik.com.sg)

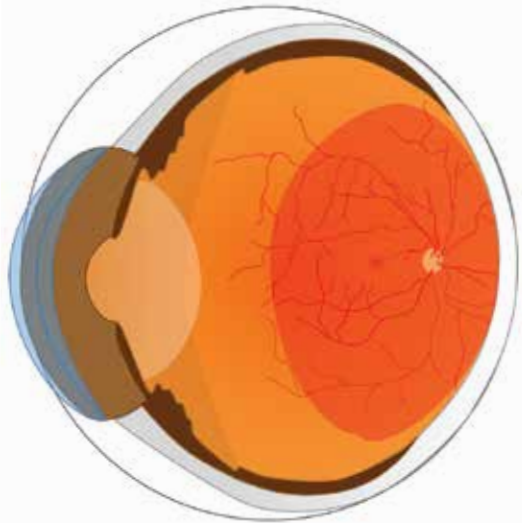
#### Disclaimer

This is a general guide. If in doubt, please consult your doctor. Information is subject to revision without notice. The contents of this leaflet are not to be reproduced in any form without the prior permission of NHG Eye Institute.

## What is uveitis?

- Uveitis is inflammation of the eye, which can present with pain, redness and blurring vision.
- If not treated, can lead to significant vision loss.
- Can affect patients of any age group or any gender.

## What is Posterior Uveitis?



Area shaded in red representing the part of the eye which is affected in posterior uveitis.

- Posterior uveitis, affects the back part of the eye involving retina and choroid.
  - An inflammation in the choroid would be called choroiditis.
  - The inflammation may also arise in, or affect, the retina (retinitis) or in the blood vessels at the back of the eye (vasculitis).
- Posterior uveitis describes where the uveitis is. It is not really a disease in itself. In fact there are a large number of uveitic conditions, which can be described as posterior uveitis. For anyone reading up about their condition, posterior uveitis is a useful term because it has features, which are different from anterior uveitis, the most common form of uveitis.

- Posterior uveitis is potentially a vision threatening uveitis and requires prompt attention, systemic investigations and also admission at times.

Few characteristic features of posterior uveitis are:

- It is usually painless
- It is more likely to impair the vision than other forms of uveitis
- Floaters are common
- Vision can be impaired suddenly or reduce worsen gradually over a period of time.

## What are the causes of Posterior Uveitis?

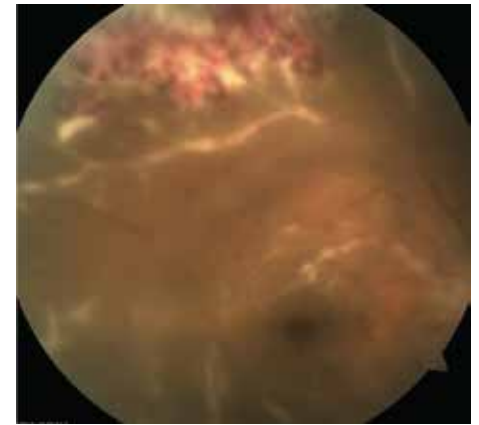
A variety of conditions can present as posterior uveitis. They all may have quite different causes. So it is often very difficult to define or name the causes of posterior uveitis.

It may be due to infectious agents like bacteria, virus, parasites etc.

Also some systemic diseases like tuberculosis, sarcoidosis can present as posterior uveitis without other generalized symptoms of the disease.

Few such examples of diseases are given below which can present as posterior uveitis:

- **Inflammatory conditions:** sarcoidosis; Vogt koyanagi Harada disease, Behcet's disease, White dot syndromes.
- **Infectious conditions secondary to bacteria, virus, parasites etc.:** ocular tuberculosis; toxoplasmosis; ocular syphilis; viral retinitis, HIV infections including cytomegalovirus retinitis etc.
- **Masquerade syndrome:** Very rarely, there may be intraocular tumors (eg. Intraocular lymphoma) which can manifest as posterior uveitis.



Fundus image of a case of retinitis and vasculitis.

## What are the complications and outcome of Posterior Uveitis?

If not diagnosed and treated on time, can lead to blindness

- Retinal detachment
- Optic atrophy
- Macular edema
- Retinal necrosis
- Complicated cataract
- Glaucoma

## What are the investigations for Posterior Uveitis?

- Battery of laboratory investigations to be done to rule out infective etiology.
- Chest X ray and if required neuroimaging.
- Local investigations such as fundus fluorescein angiogram and optical coherence tomography (OCT) are done to assess the status of retinal vasculature and macula respectively.